Kalcium a intrakoronární imaging

IVI u komplexních PCI

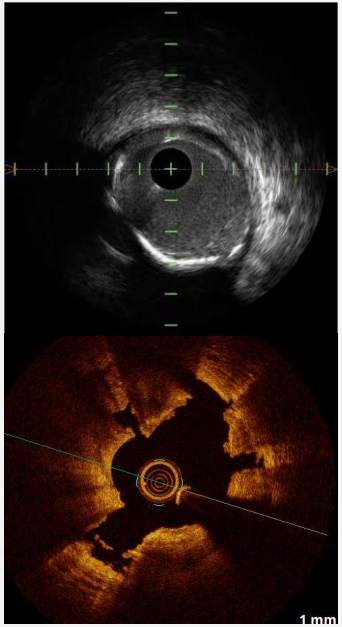

Jan Kaňovský

WS ČAIK 3.4.2025

INTERNÍ KARDIOLOGICKÁ KLINIKA FN BRNO a LF MU

FAKULTNÍ NEMOCNICE BRNO

MUNI MED

Deklarace konfliktu zájmů

	Nemám konflikt zájmů	Mám konflikt zájmů	Specifikace konfliktu (vyjmenujte subjekty, firmy či instituce, se kterými Vaše spolupráce může vést ke konfliktu zájmů)
Zaměstnanecký poměr	X		
Vlastník / akcionář	X		
Konzultant	X		
Přednášková činnost		X	Abbott
Člen poradních sborů (advisory boards)	X		
Podpora výzkumu / granty	X		
Jiné honoráře (např. za klinické studie či registry)	X		

Klíčový koncept – kalcium je protivník

- Kalcifikace jsou klíčovým prediktorem suboptimálního výsledku/neúspěchu PCI*
- Nepodceňujme svého protivníka
- Intravaskulární imaging může být náš spojenec

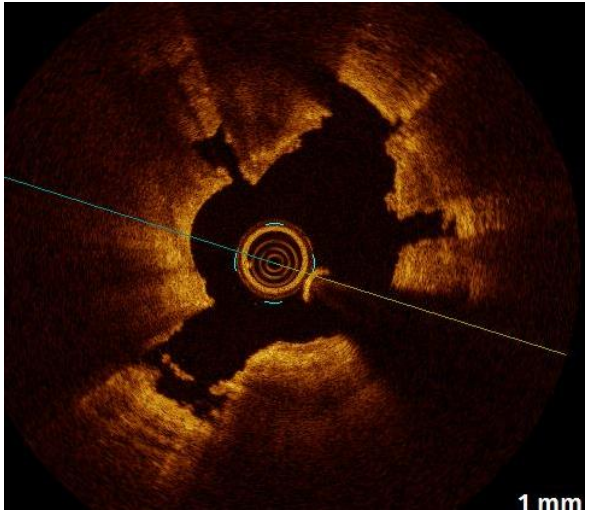

post IVL cracks

*Fujino et al., EuroIntervention 2018

Poznej svého protivníka

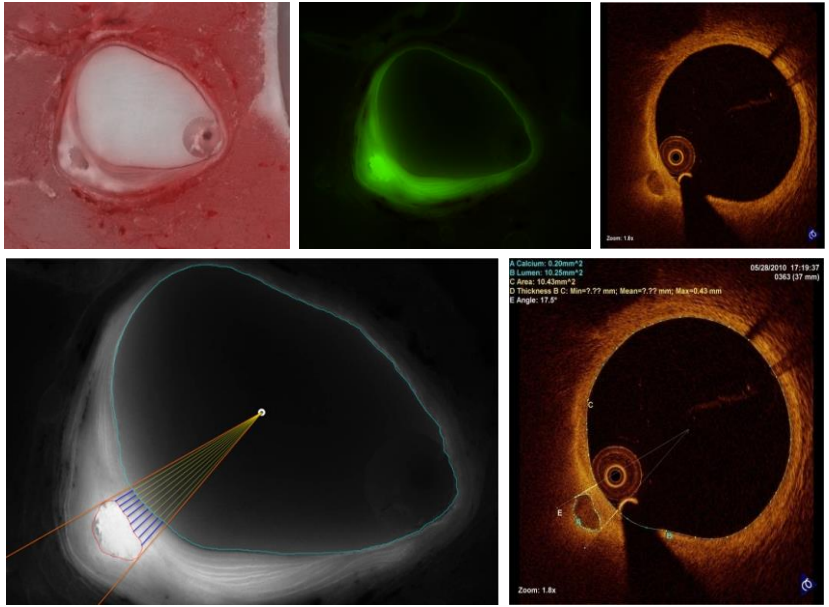

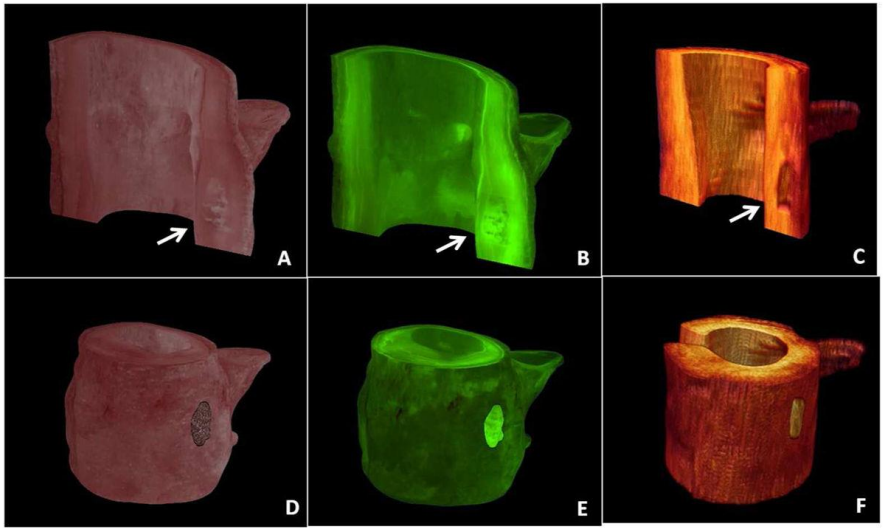

Klíčové parametry v distribuci kalcia:
angle, thickness and depth

Mehanna et al. Circ J 2013

	Coronary Angiography	CT	IVUS	RF-IVUS (IVUS-VH)	OCT
IMAGING MODALITIES	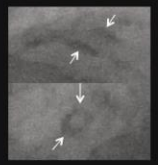	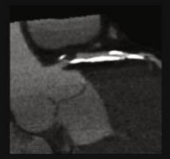	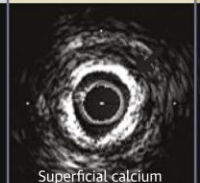 Superficial calcium detection	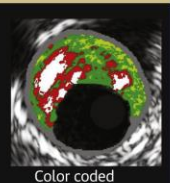 Color coded tissue composition	Sharp delineation of calcium area is possible
Detection of coronary artery calcium	+	+++	+++	+++	++++
Localization of coronary artery calcium	+	+++	+++	+++	++++
Quantification of coronary artery calcium	+	+++	++	+++	++++
		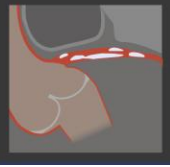			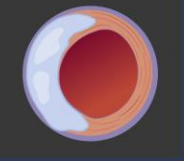

Intravaskulární imaging: detekce a kvantifikace kalcia

Mintz, JACC Cardiovasc Imaging 2015

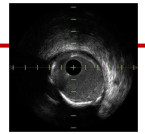



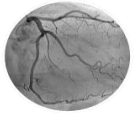

Calcium detected	73% of lesions	38% of lesions
Classification	Deep Superficial Nodular Eccentric Concentric	Mild Moderate severe
Distribution & thickness	Calcium score	Poor

Adaptováno - Mintz et al., Circulation 1995

ABSENCE OF INTRAVASCULAR IMAGING

↓

UNDERESTIMATION OF CALCIUM

↓

INCREASED LIKELIHOOD OF IMPROPER VESSEL PREP

↓

- STENT UNDEREXPANSION
- INCREASE RISK OF COMPLICATIONS
- STENT MALAPPOSITION
- MORE STENTS
- LONGER PROCEDURES

OCT Calcium score

Rule of 5's

- 0.5 mm thickness
- 5.0 mm long
- 50% vessel arc

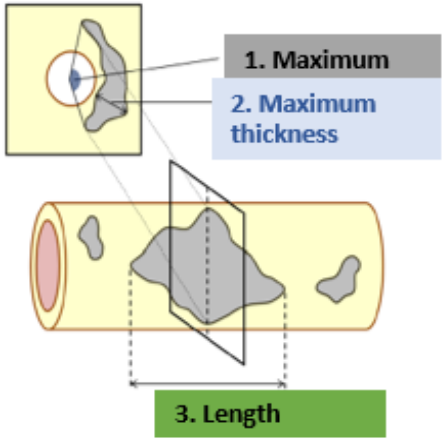

OCT-Based Calcium Volume Index Score

1. Maximum Calcium Angle (°)	≤ 90°	▶ 0 point
	90° < Angle ≤ 180°	▶ 1 point
	> 180°	▶ 2 points
2. Maximum Calcium Thickness (mm)	≤ 0.5 mm	▶ 0 point
	> 0.5 mm	▶ 1 point
3. Calcium Length (mm)	≤ 5.0 mm	▶ 0 point
	> 5.0 mm	▶ 1 point
Total score	**0 to 4 points**	

Fujino et al., EuroIntervention 2018

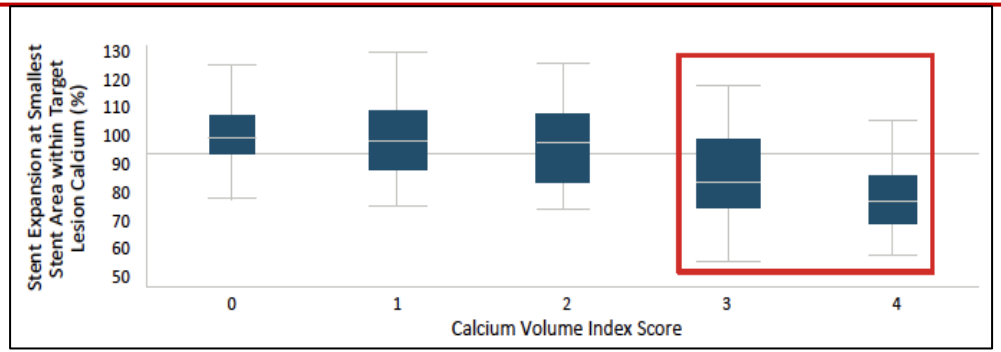

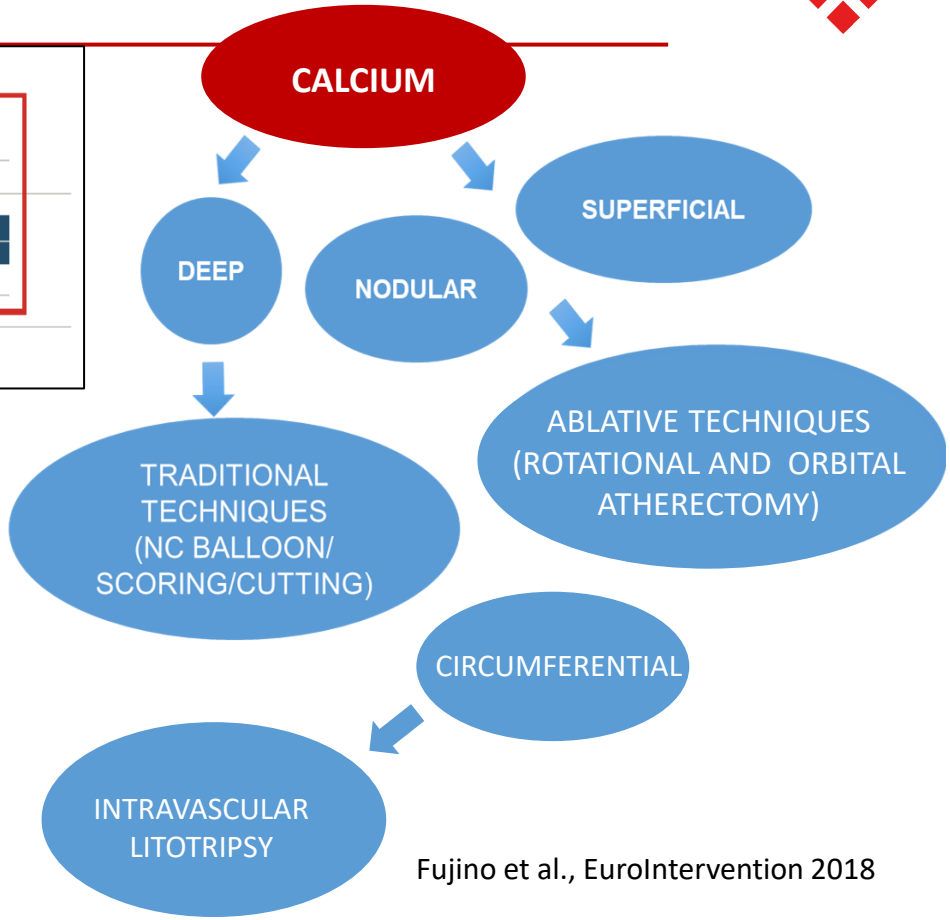

Zvyšující se riziko nedostatečné expanze stentu s rostoucím OCT Ca Volume Index score

Fujino et al., EuroIntervention 2018

IVUS Calcium Score

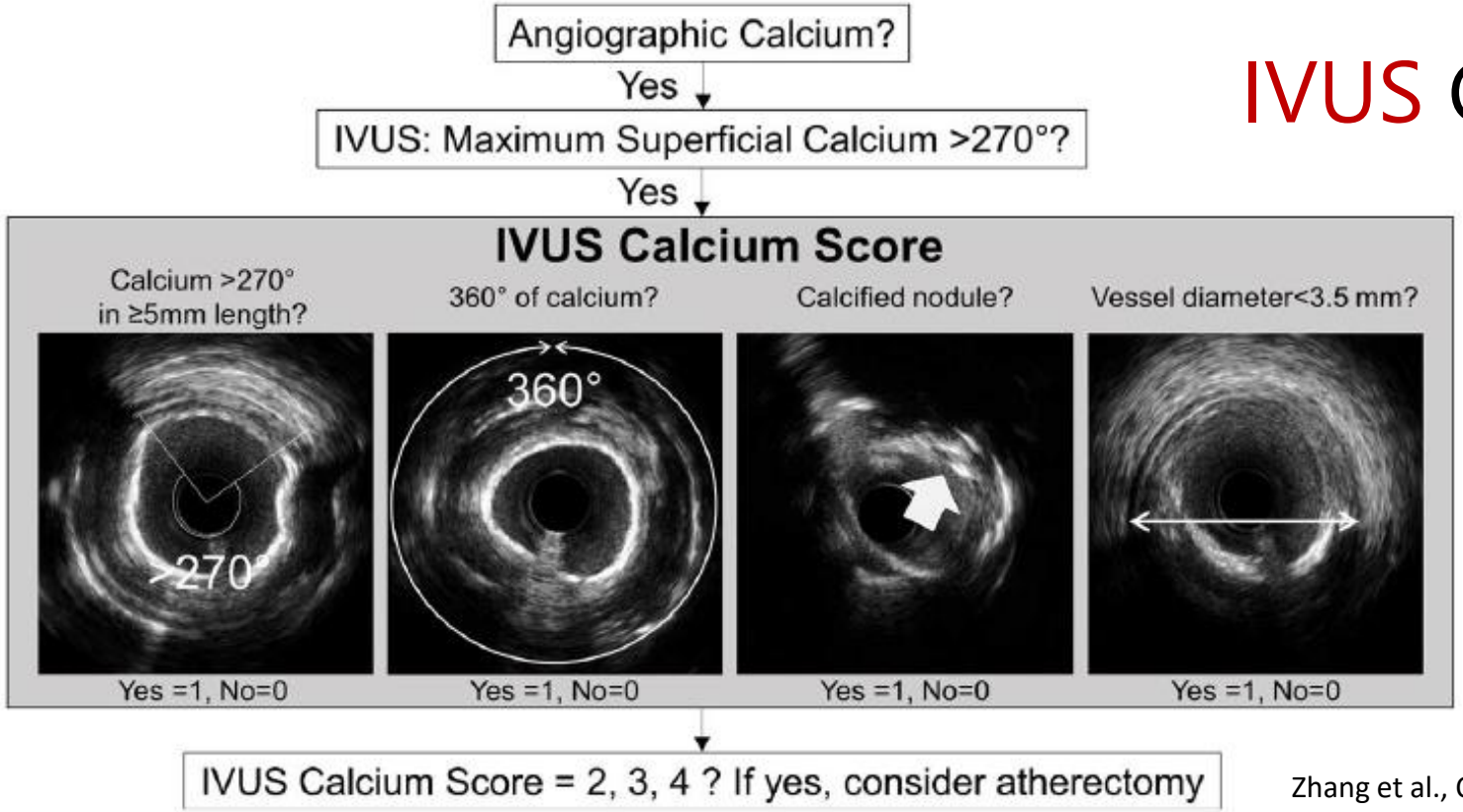

Zhang et al., Circ Cardiovasc Interv 2018

OCT a IVUS
algoritmus kalcifikací

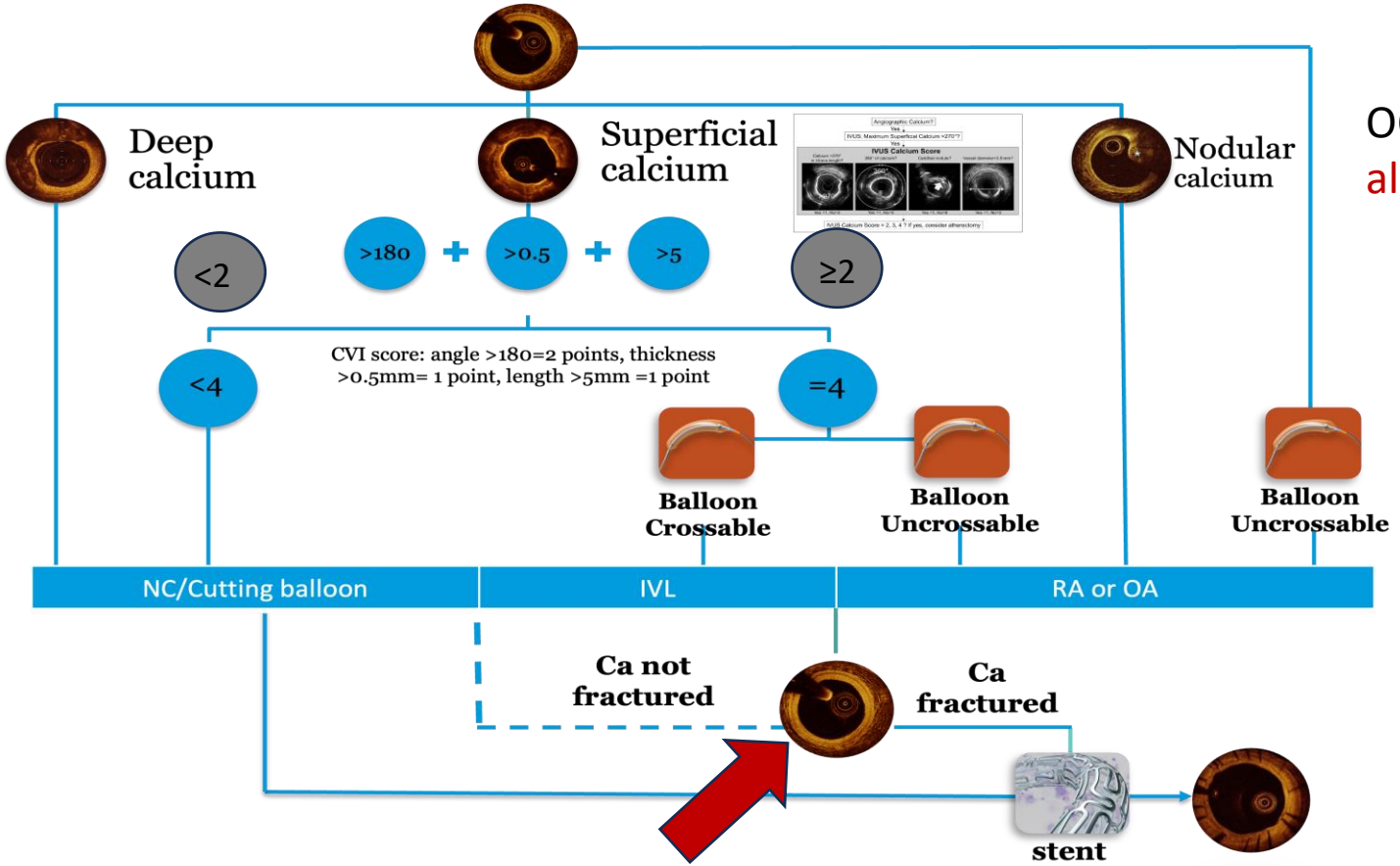

Cíl v zápase

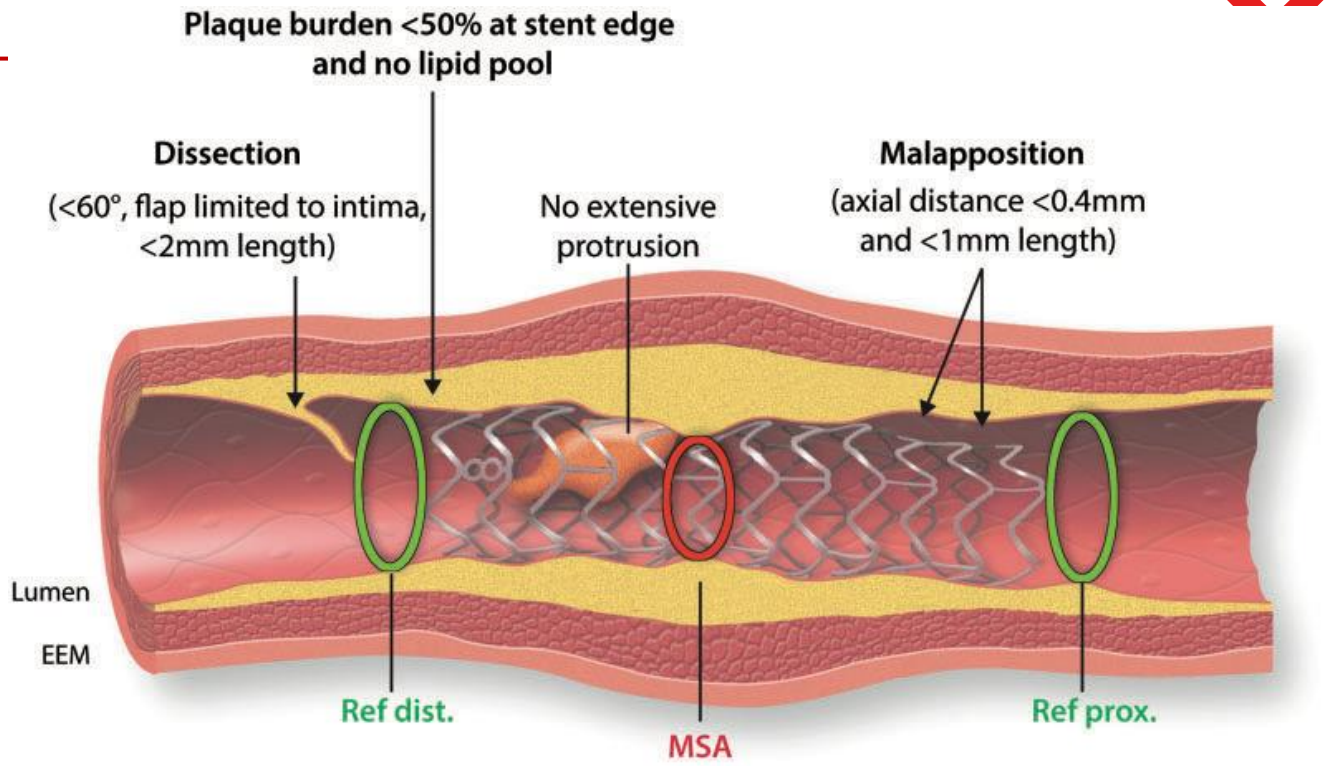

MSA>5.5cm² (IVUS) and >4.5cm² OCT

MSA/average reference lumen > 80%

Räber et al., EHJ 2018

Case report

- muž, *1953
- hypertenze, HPLP, diabetes II. typu na PAD
- pozitivní ergometrie 12/2024 (horiz. deprese ST V3-6)
- EF LK 65%, bez poruch kinetiky, bez vady, lehká hyLK

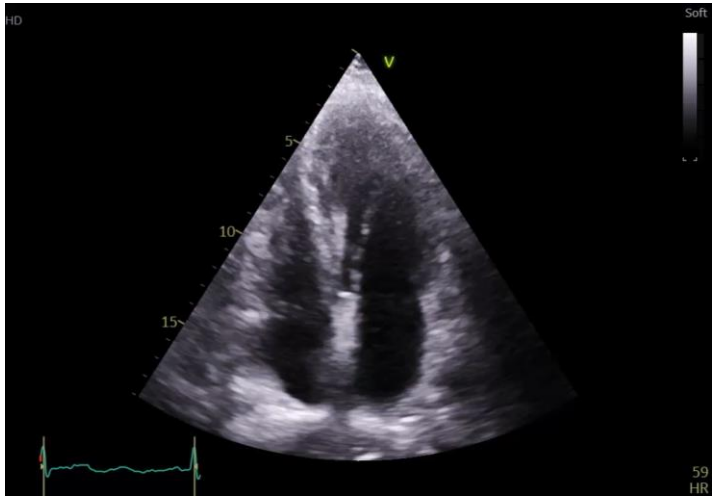

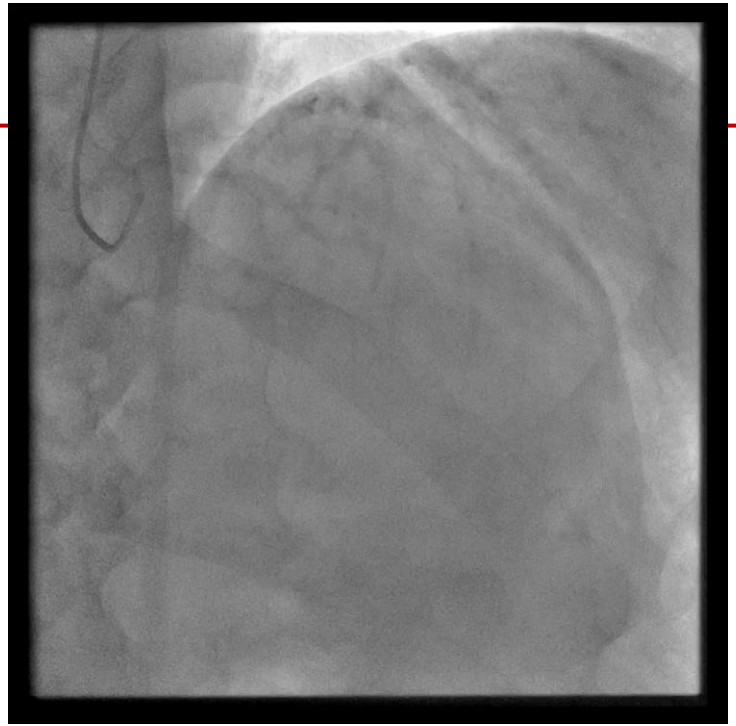

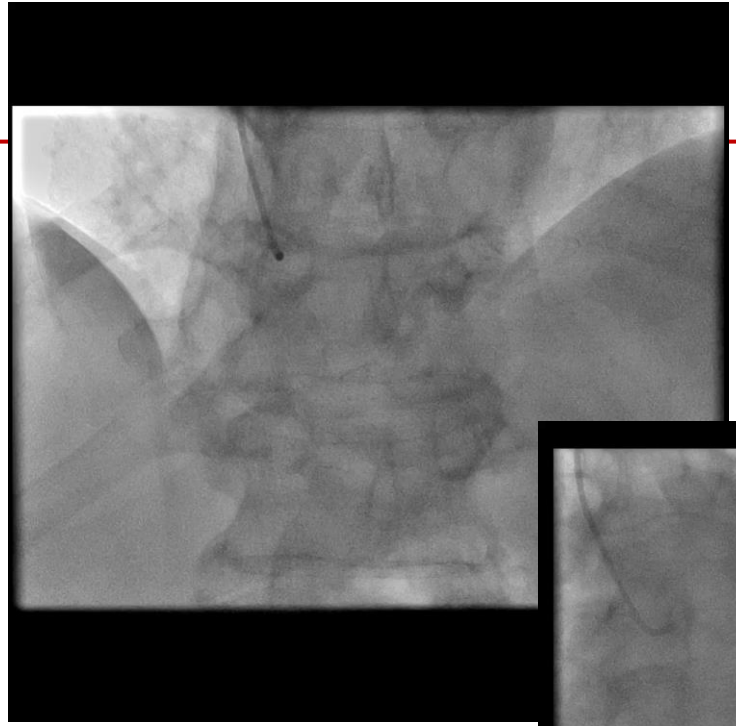

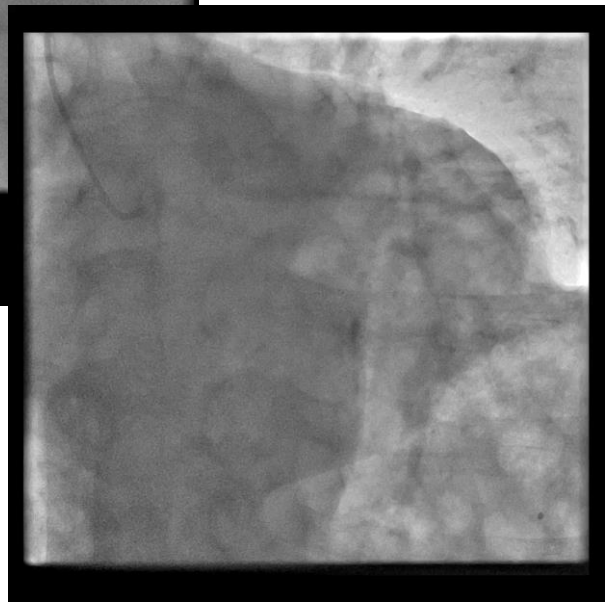

SKG 1/2025

60-70% prox. RIA, 90% RMS,
60-70% stř./dist. ACD

Doporučení?

Heart team doporučení

- PCI RMS
- Funkční vyšetření RIA a ev. PCI
- Funkční vyšetření ACD a ev. PCI

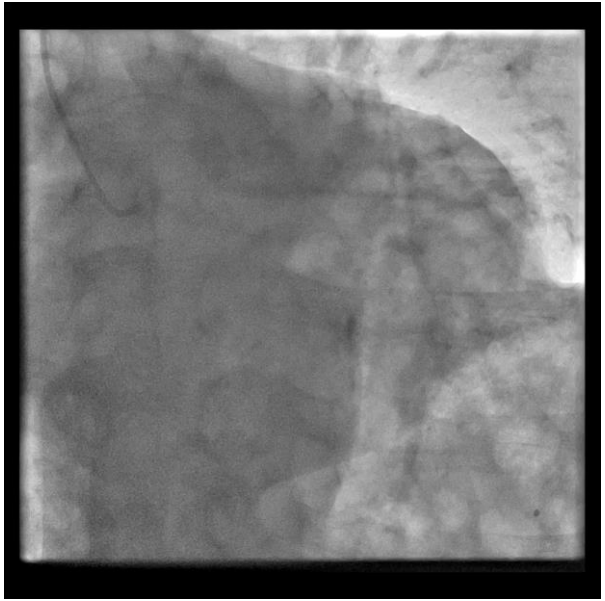

PCI RMS 2/2025

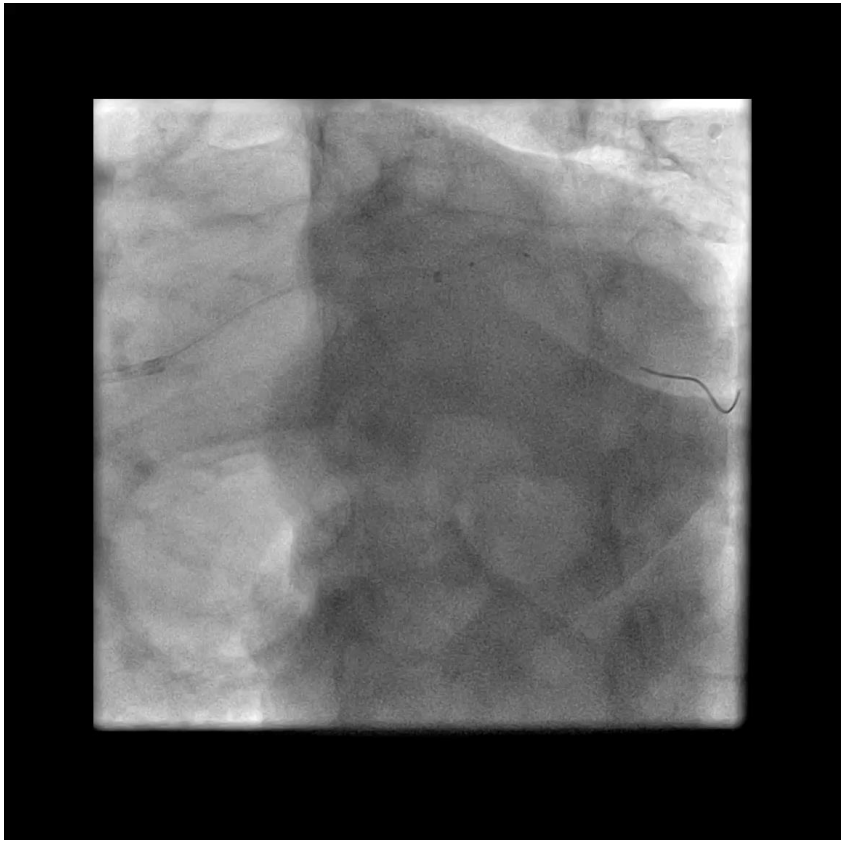

PCI RMS 2/2025

- XB 3,5F6
- support extenze
- predilatace NC 2,25-2,5mm
- 1x sirDES zničen v ohybu
- 1x everDES 2,75mm implantován
- obtížná postdil NC 3,0

- Kontrast 193ml, skia 21,5min

Funkční vyš. ACD 2/2025

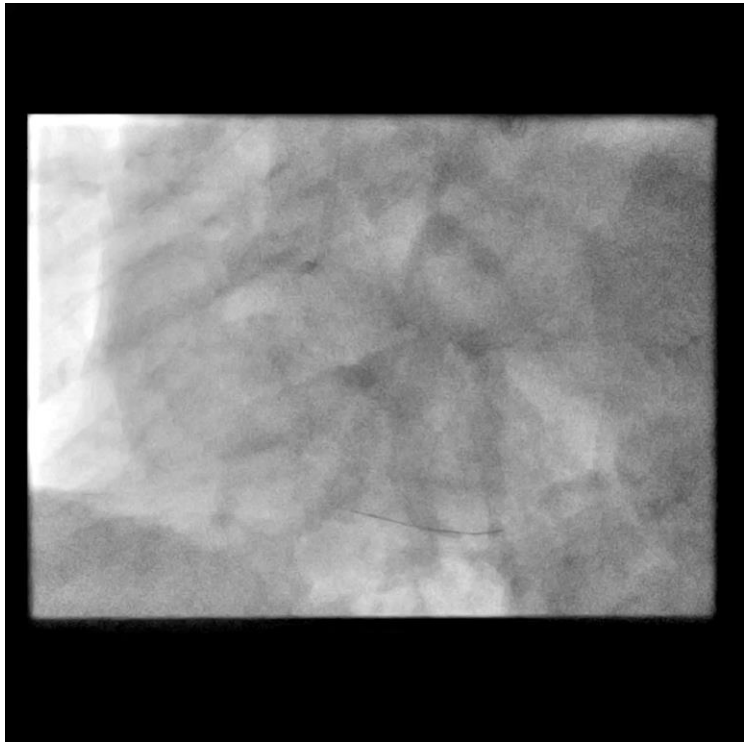

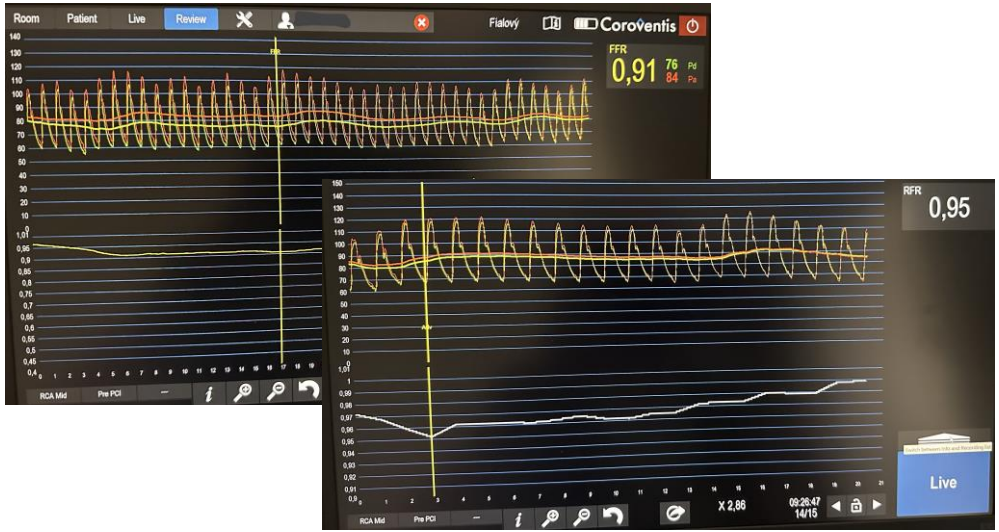

- RFR 0,98
- FFR 0,91
- nevýznamná léze

Funkční vyš. RIA 2/2025

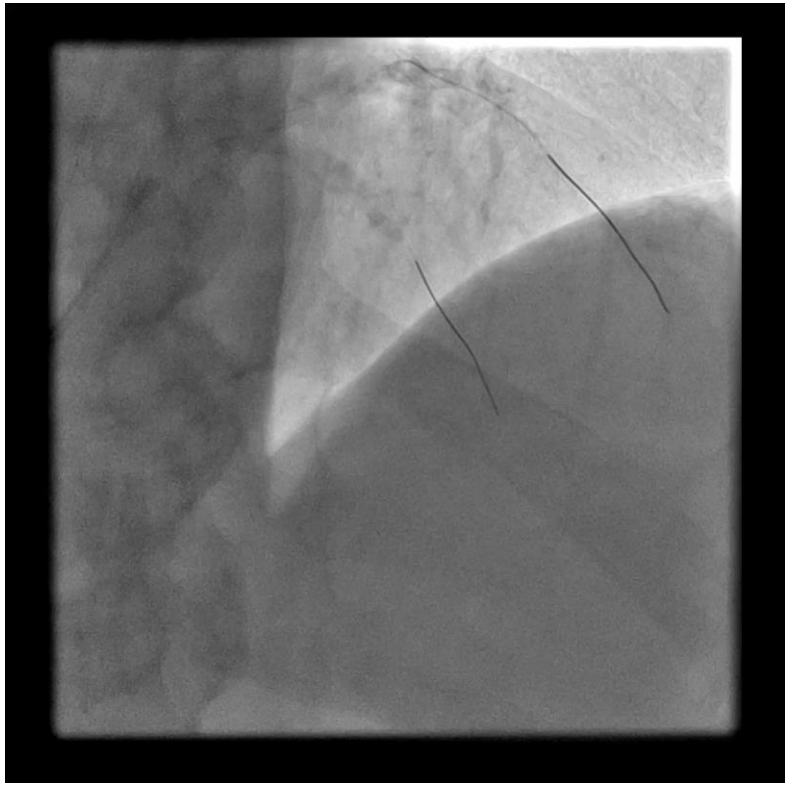

- RFR 0,86
- FFR 0,73 významná léze
- CFR 4,1, IMR 7 mikrocirkulace bez patol.

PCI RIA 3/2025

Sion Blue, nelze proniknout katetrem OCT

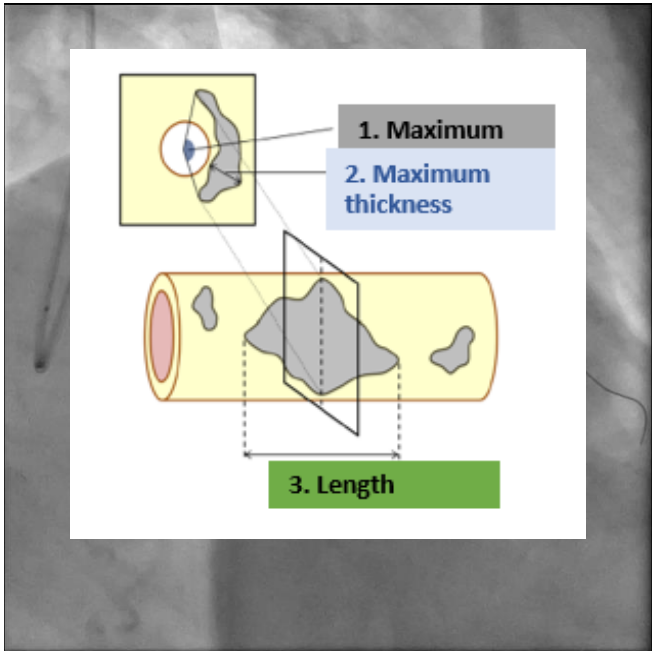

Heavy calcifications,
OCT Ca score 3

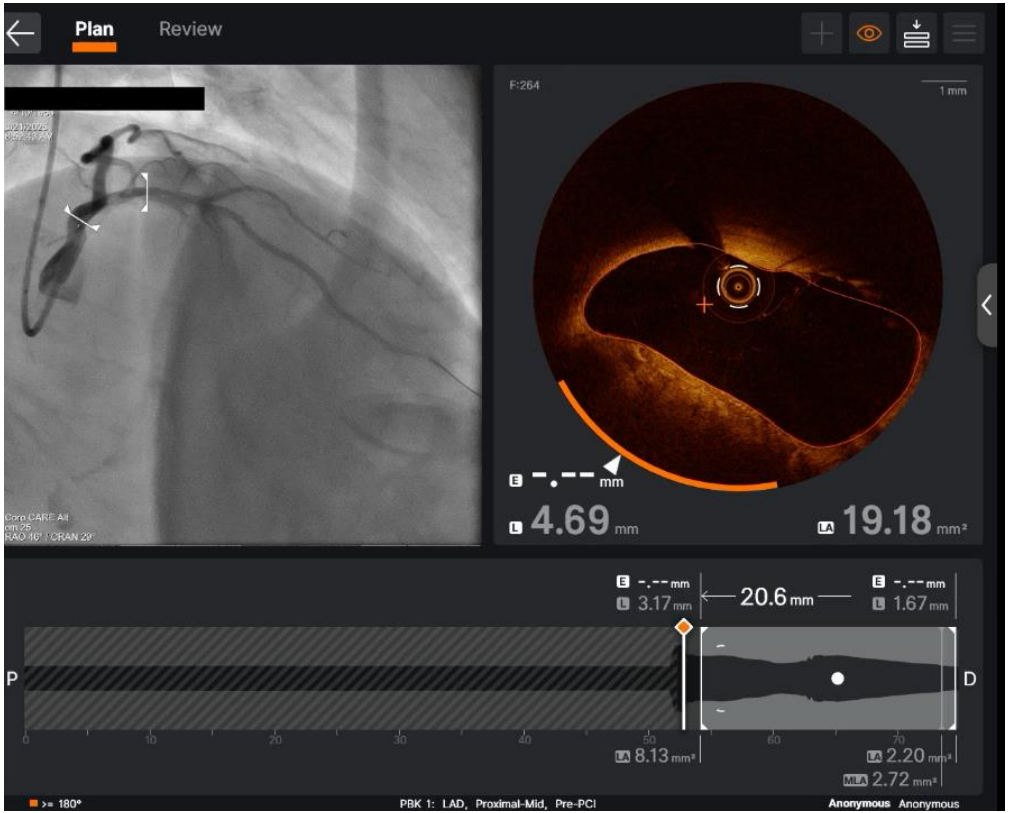

PCI RIA 3/2025

Orbitální aterektomie 6x low speed, 2x high speed

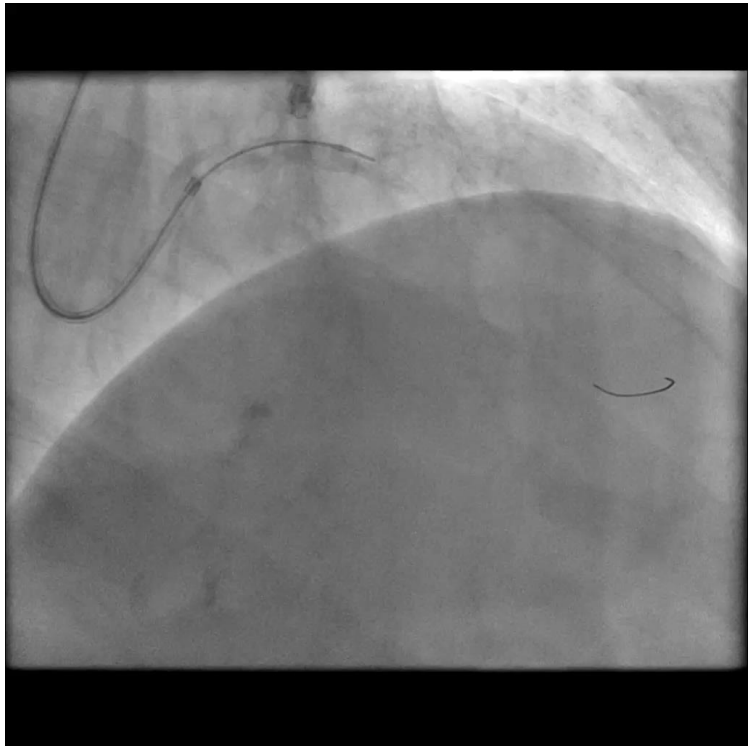

Před

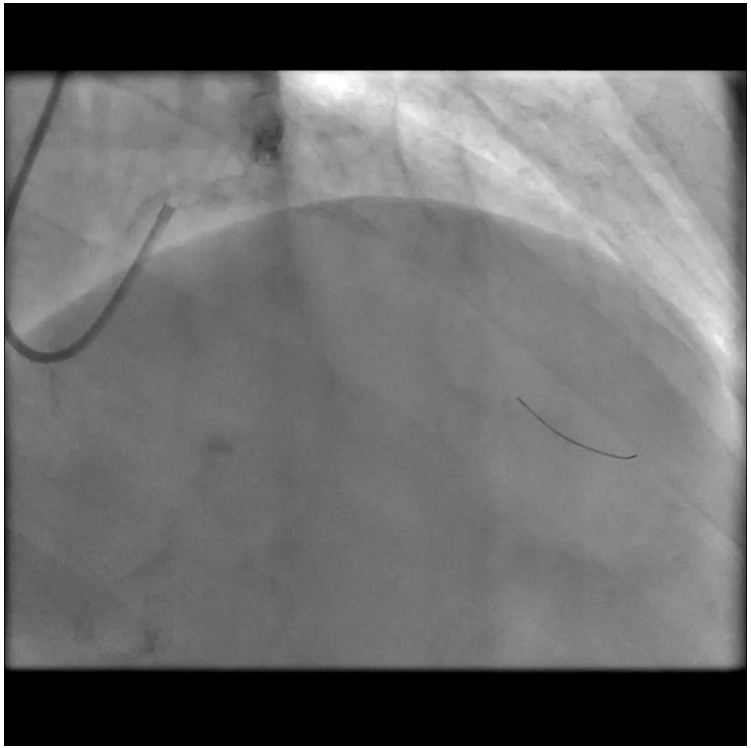

Po

PCI RIA 3/2025

Orbitální aterektomie 6x low speed, 2x high speed

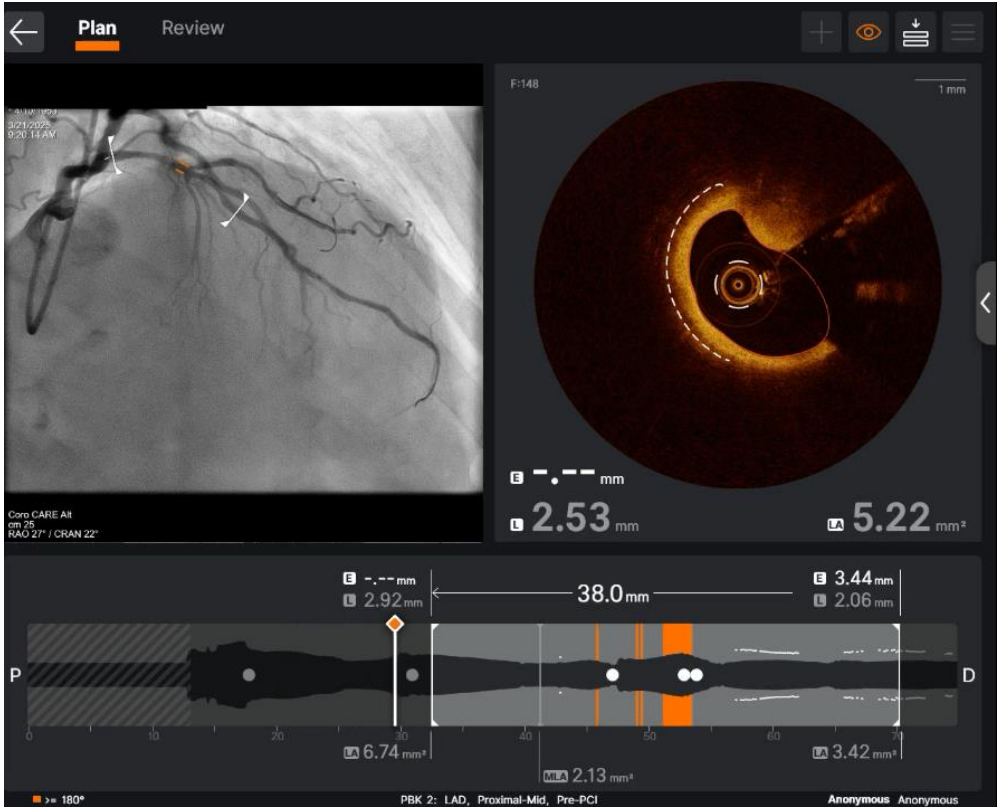

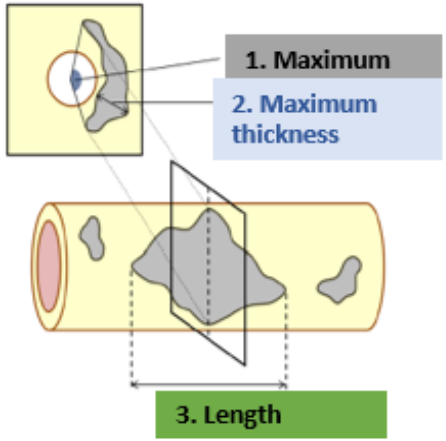

Heavy calcifications,
OCT Ca score 4

Příprava:
NC 2,5-3,5mm

OCT

Plán:
DES 2,75x23mm
DES 3,5x28mm
Postdil. NC až 3,75mm

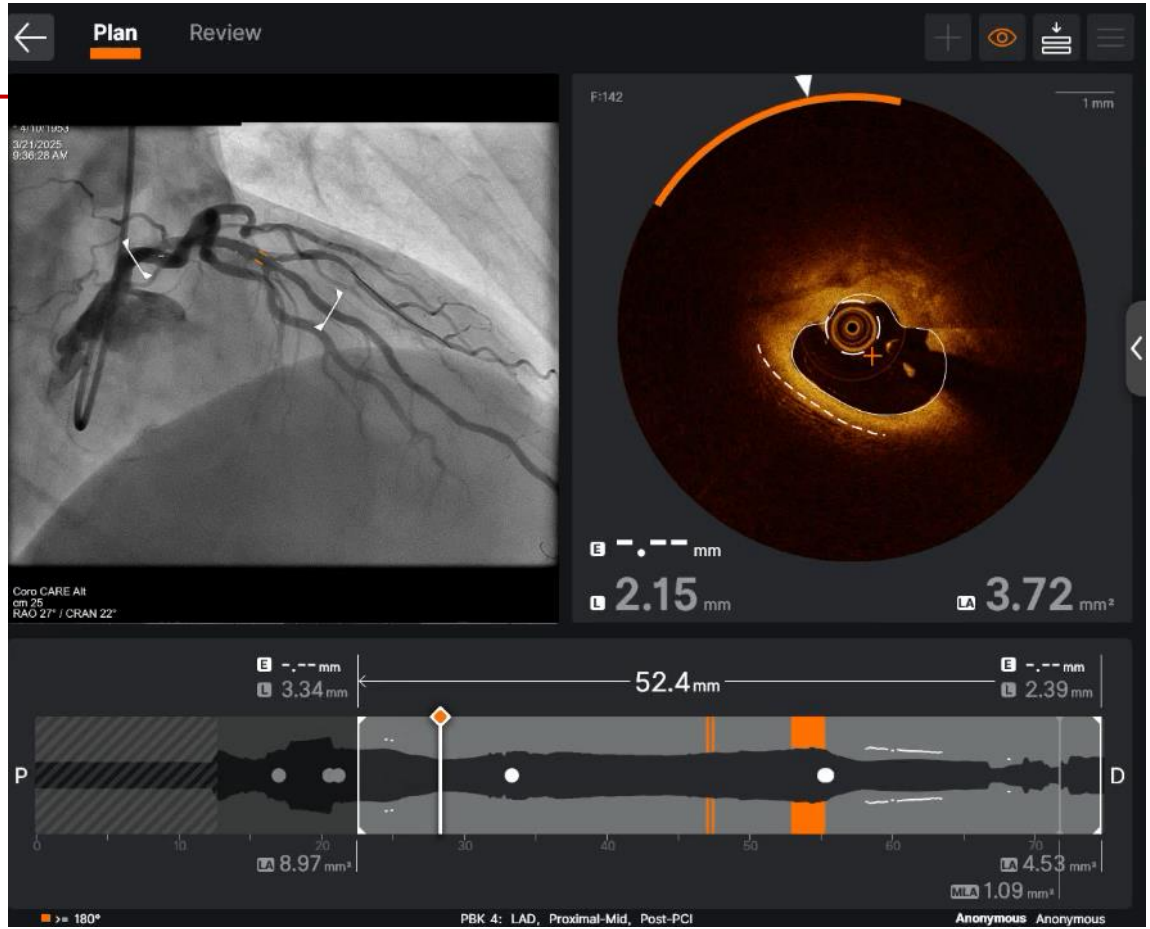

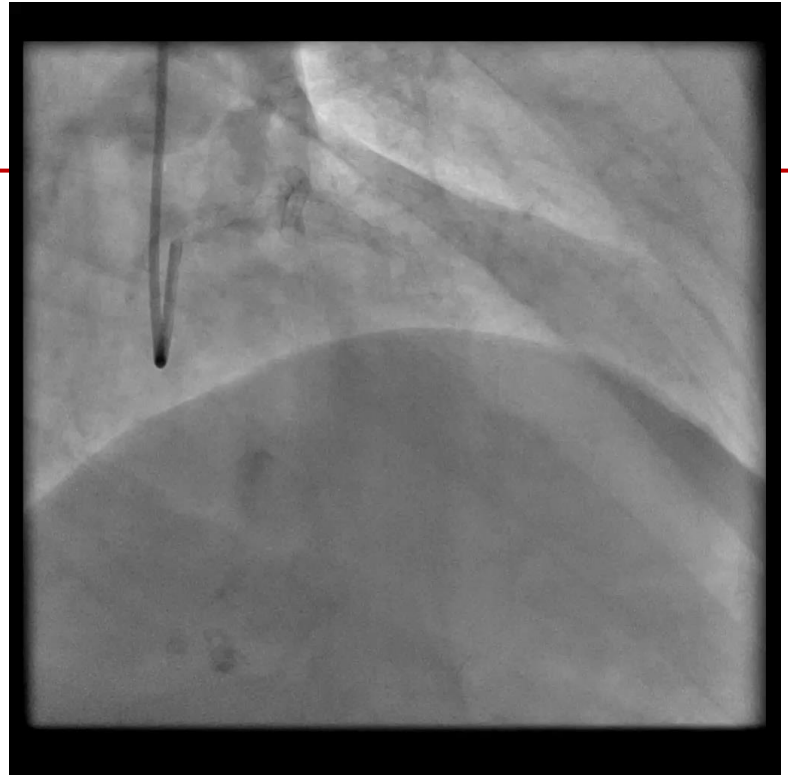

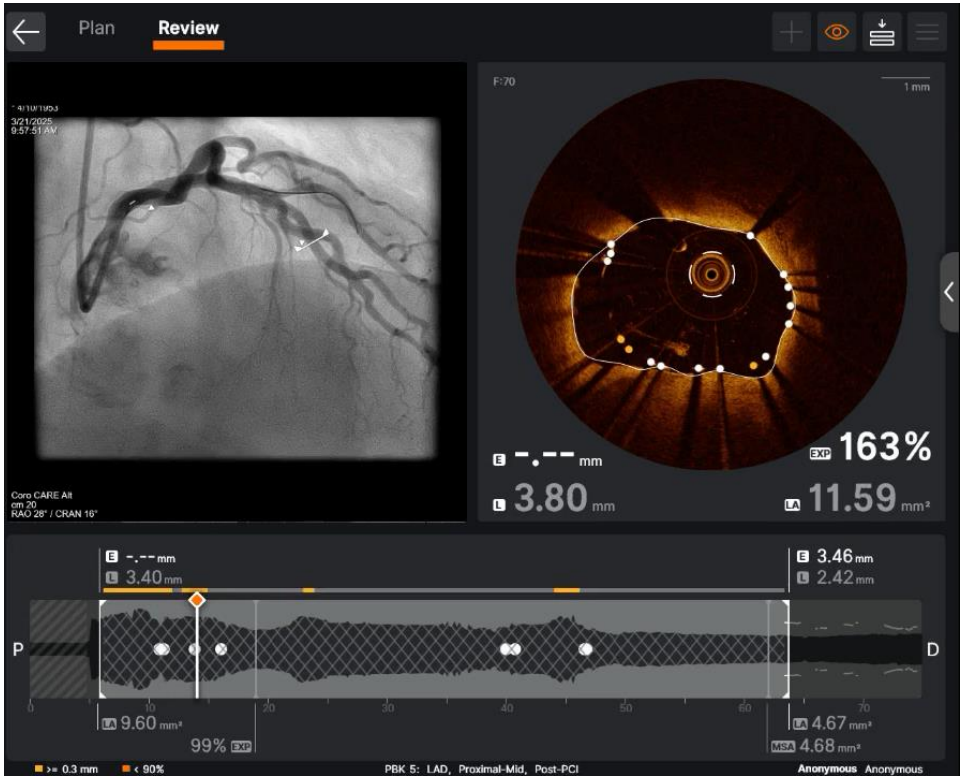

Optimální výsledek
Dobrá expanze 99%+
Markery malapozice u bočních větví
Kontrast 165ml, skia 12,5min

Klíčové koncepty (znovu)

- Kalcium je náš protivník
- Nikdy nepodceňujme svého protivníka
- Intravaskulární imaging může být náš spojenec
- V komplexních kalcifiovaných lézích, spojenec může pomoci s:
  - identifikací kalcia
  - zhodnocení tíže kalcifikací
  - naplánování správné strategie přípravy léze
  - kontrolou průběhu PCI
  - optimalizovat finální výsledek PCI

thank you